

CASE REPORT

CYTOLOGY OF CAROTID BODY TUMOR – AN ATYPICAL PRESENTATION

*Suchitra K.N., Sreelekha B.V., Jayasree K., and Bharath C.

Department of Pathology, VIMS, Ballari, India

ARTICLE INFO

Article History:

Received 14th July, 2016
Received in revised form
25th August, 2016
Accepted 18th September, 2016
Published online 31st October, 2016

Keywords:

Carotid body Tumor,
Atypical Presentation,
Fine Needle Aspiration Cytology.

ABSTRACT

Paragangliomas are tumors arising from the paraganglion tissue which is well represented in the head and neck. Carotid body tumor is a paraganglioma situated at the bifurcation of the common carotid artery. We describe here a case of 32 year old male with painless swelling on the right side of the neck clinically diagnosed as right jugulodigastric region lymphadenopathy. Fine needle aspiration cytology (FNAC) of the swelling was done. On examination, the aspirate was haemorrhagic and showed cohesive clusters of round to oval neoplastic cells arranged in acinar pattern with finely granular chromatin and moderate amount of cytoplasm interspersed by spindle cells. Based on these cytologic findings and the location of the swelling, a diagnosis of carotid body tumor was made. The tumor was excised and findings confirmed on histopathological examination. This was a rare finding because diagnosis was made in a young male and was an incidental finding with no clinical history suggestive of carotid body tumor. This case adds to the existing literature on cytological diagnosis of carotid body tumor, further attesting to its safety and accuracy.

INTRODUCTION

Carotid body tumors are rare benign slow growing neoplasms also called paragangliomas (Majumdar, 2014). These tumors are also sometimes referred to as chemodectomas because the neuroendocrine cells that make up these lesions sense oxygen and carbon dioxide tensions within adjacent vessels (Vinay Kumar, 2005). We describe the FNAC findings of one such tumor in a 32 year old male.

Case report

A 32 year old male presented to the surgery outpatient department with a painless swelling on the right side of the neck of 5 days duration. No other significant history noted in this patient. Clinically it was diagnosed as right jugulodigastric lymphadenopathy. This patient was subjected for Fine needle aspiration cytology (FNAC).

On examination non tender swelling in the right jugulodigastric region measuring 1x1 cm, firm, with restricted mobility was noted. FNAC done with a 23G needle, yielded frank blood. Smears prepared were stained with haematoxylin and eosin. On microscopy, haemorrhagic smears showed moderate cellularity with neoplastic cells arranged as poorly cohesive clusters, acinar pattern and scattered singly. These cells had indistinct cytoplasmic borders, round to ovoid nucleus with moderate amount of fine granular cytoplasm showing mild to moderate pleomorphism.

Many spindle cells having elongated to bland nucleus and indistinct cytoplasm arranged in papillary pattern admixed with neoplastic cells and scattered singly were seen (Fig.1, 2, 3). Based on these cytological features and the location of the tumor a diagnosis of right carotid body tumor was made. After 1 week the mass was excised and sent for histopathological examination. Haematoxylin and eosin stained section showed a capsulated tumor closely packed with tumor cells arranged in trabecular, nesting and organoid pattern separated by highly vascularized fibrous septa giving a zelballen pattern appearance. The tumor cells were round to ovoid, with moderate cytoplasm and large bland looking nuclei. The mitotic activity appeared to be scant. These features favored a diagnosis of carotid body tumor (Fig. 4, 5)

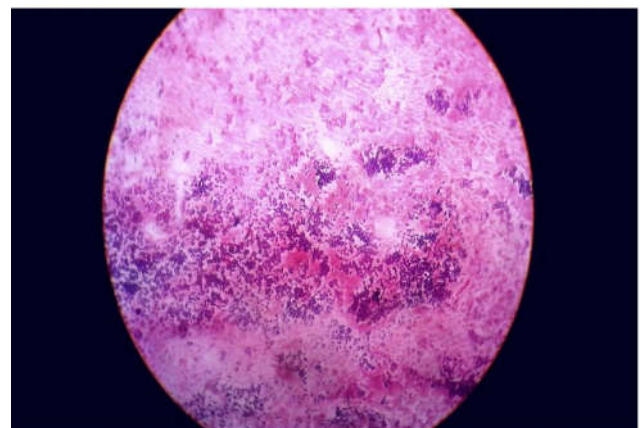


Fig.1. (5x,H and E) smear shows oval and spindle shaped cells arranged in acinar pattern in hemorrhagic background

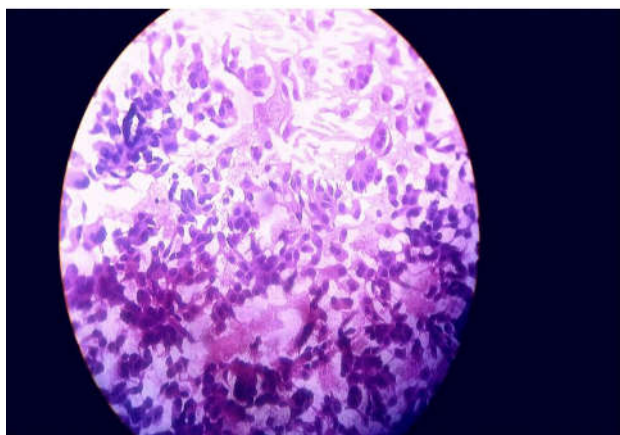


Fig. 2. (40x,H and E) smear shows bipopulation of oval and spindle shaped cells in loosely cohesive clusters and scattered singly having pink cytoplasm

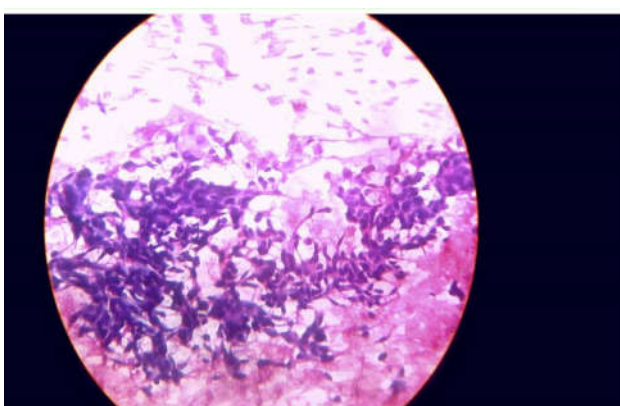


Fig. 3. (40x, H and E) smear shows predominantly spindle shaped cells in cohesive clusters

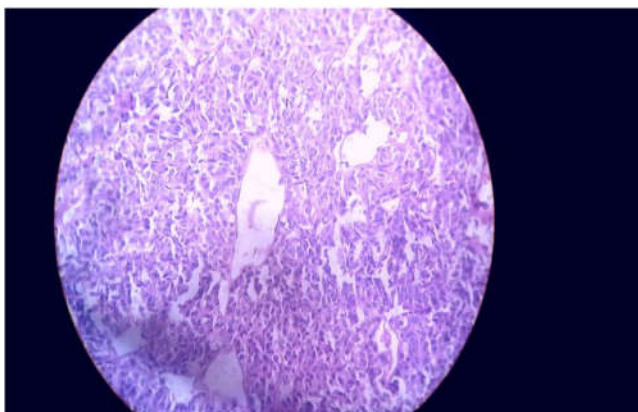


Fig. 4. (40x, H and E) section shows tumors cells separated by thin walled blood vessels

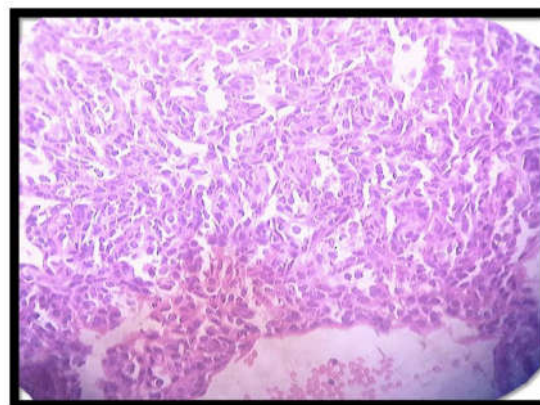


Fig. 5. (40x, H and E) section shows oval cells arranged in zellballen pattern

DISCUSSION

Paraganglioma is a tumor of paraganglion cells and due to its firm adherence to the underlying tissue often misinterpreted as malignancy (Dukkipati, 2015). Paragangliomas located outside the adrenal gland that are obviously chromaffin and associated with clinical features suggestive of epinephrine or norepinephrine secretion arise from orthosympathetic related paraganglia whereas most of the non chromaffin, non functioning paragangliomas originate from parasymphathetic related organs (Juan Rosai, 2004). Carotid body tumors are usually benign but occasionally produce local and distant metastasis (Dukkipati, 2015).

Carotid body tumors vary in incidence from 7% to 29% of parapharyngeal tumors. The incidence increases to 79% at high altitudes. Presentation may be unilateral or bilateral and 10% are familial, with female gender preponderance, that is 8.3:1 at high altitude as compared to 2:1 at lower altitude. The average age at presentation is between 35 to 50 years (Majumdar, 2014). History suggestive of uncontrolled hypertension, facial flushing, excessive sweating suggestive of catecholamine secreting tumor were absent in our case. Our's was an incidental finding. Differential diagnosis include medullary carcinoma of thyroid, carcinoid, metastatic carcinoma (Pranab Dey, 2015). Immunohistochemically paragangliomas are positive for synaptophysin. Medullary carcinoma of thyroid is positive for synaptophysin, calcitonin and thyroid transcription factor (TTF). Carcinoid is positive for synaptophysin. Metastatic carcinoma is positive for cytokeratin (Pranab Dey, 2015). Imaging modalities like Doppler, ultrasound, contrast enhanced CT Scan, MRI, MRA and carotid angiography are the main stay of diagnosis for carotid body tumors. (Nuri *et al.*, 2005) Carotid angiography shows splaying of carotid vessel along with tumor blush called the Lyre's sign (Handa, 2005).

Differential diagnosis of cervical paraganglioma

	Paraganglioma	Medullary carcinoma of thyroid	Carcinoid	Metastatic carcinoma
CYTOLOGY				
1	Aspiration	Vascular bloody	Cellular	Cellular
2	Distribution of cells	Syncytial clusters, discrete cells	Discrete cells	Clusters
3	Rosettes	Occasional	Absent	Absent
4	Chromatin	Bland chromatin	Fine chromatin	Salt and pepper
5	Intranuclear inclusion	Present	Occasionally present	Absent

Conclusion

The above study suggests that differential diagnosis of paragangliomas should always be considered during the diagnostic work up of neck lesions, as preoperative diagnosis of carotid body tumor is important for the surgeon because of the possibility of severe hemorrhage and damage to the carotid artery at diagnostic excisional biopsy.

REFERENCES

- Dukkipati, K. *et al.* 2015. Fine needle aspiration cytology diagnosis of paraganglioma (carotid body tumor). Journal of Dr. NTR University of Health Sciences. 4(1):42-3.
- Handa, U. *et al.* 2005. Parapharyngeal paraganglioma: Diagnosis on Fine needle aspiration. *American Journal of Otolaryngol*, 26: 360-1.
- Juan Rosai, 2004. Adrenal gland and other paraganglia. Rosai and Ackerman's surgical pathology. Mosby Elsevier, China.Pp.1142-1146.
- Majumdar, A. *et al.* 2014. Carotid body paraganglioma fine needle aspiration cytology. *Journal of Medicine in the topics*. 16(1):45-6.
- Nuri, M.M.H *et al.* 2005. Carotid body tumor. *Pakistan Armed Forces Medical Journal*. 3: 265-7.
- Pranab Dey. 2015. Head, Neck, and Orbital Lesion. Fine needle aspiration cytology Interpretation and diagnostic difficulties. Jaypee, New Delhi.Pp.53-55.
- Vinay kumar, Abul K. Abbas, Nelson Fausto.2005.Head and Neck.Robbins and Cotran pathologic basis of disease. Saunders Elsevier, New Delhi. Pp.789-790.
