



ISSN : 2350-0743

www.ijramr.com



International Journal of Recent Advances in Multidisciplinary Research

Vol. 11, Issue 01, pp.9503-9505, January, 2024

CASE REPORT

ADRENAL TUMORS COMPLICATING PREGNANCY: TWO CASE REPORTS AND LITERATURE REVIEW

*Dr. Vishal Naik, Dr. Shivendra, Dr. Sreeniketh Reddy, Dr. Prudhvi Reddy Amulya Aggarwal and Dr. Kasi Vishwanath

Rajarajeswari Medical College and Hospital, Bangalore, India

ARTICLE INFO

Article History:

Received 27th October, 2023

Received in revised form

19th November, 2023

Accepted 15th December, 2023

Published online 24th January, 2024

Key Words:

Tumors in Pregnancy, Laparoscopy in Pregnancy.

ABSTRACT

Most adrenal tumors are identified incidentally and non-functional. However, hormone-secreting tumors can result morbidity and mortality. Hemodynamic lability and hypertension in pregnancy are associated with worse maternal and fetal outcomes.

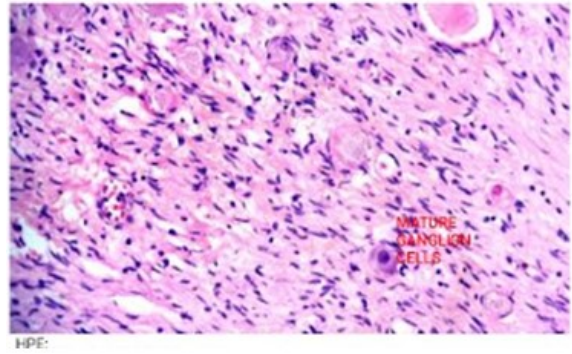
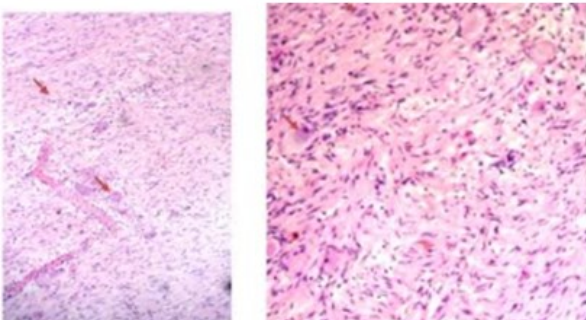
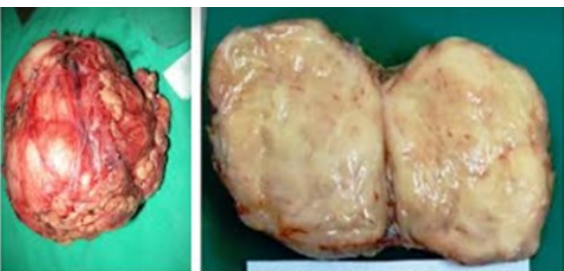
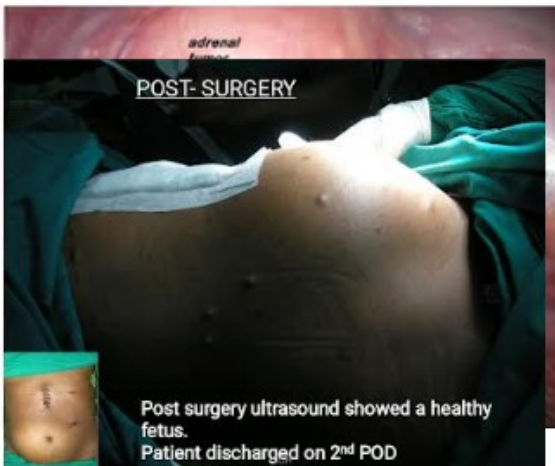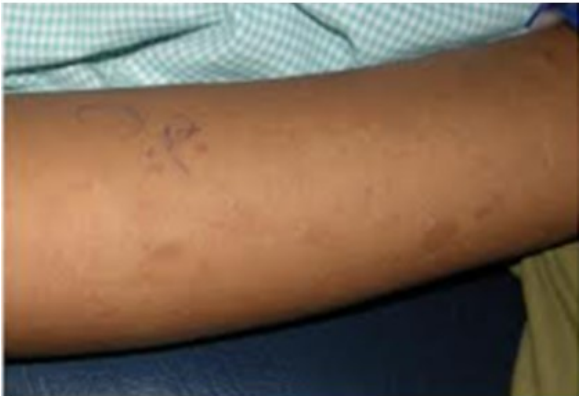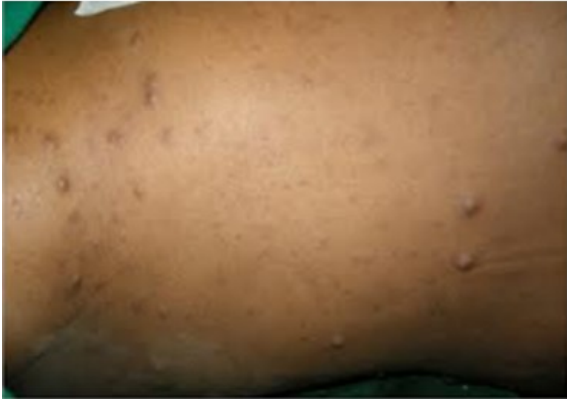INTRODUCTION

Most adrenal tumors are identified incidentally and non-functional. However, hormone-secreting tumors can result morbidity and mortality. Hemodynamic lability and hypertension in pregnancy are associated with worse maternal and fetal outcomes. Achieving a diagnosis of hormone excess due to adrenal tumors can be clinically more difficult in the gravid patient due to normal physiologic alterations in hormones and symptoms related to pregnancy.

Case History: Our First case is a 26-year-old primigravida who presented with history of 22 weeks amenorrhea. Her 2nd trimester anomaly scan revealed a heterogenous mass of 6*4cms over the left kidney with a single live intrauterine fetus of AGA. She was referred to us in view of the same. She had occasional headaches with borderline high blood pressure measurements of 150/90 during her ANC visits. On examination she was normotensive on multiple occasions. But she had multiple neurofibromatosis and café-au-lait spots. Her cardiorespiratory system examination was normal. MRI was done which showed 6*8 cms left adrenal mas with mixed attenuation. 24hr- urinary catecholamines/VMA was normal. Plasma adrenaline and nor-epinephrine levels were high normal. Fundal examination was normal. Serum potassium was low.

ECG and Echo was normal except for few ectopic. Concerns were that a diagnosis of phaeochromocytoma could not be conclusively ruled out which could result in high chance of mortality at childbirth. Patient was over 22 weeks gravid, hence terminating pregnancy had its own challenges and 25% of tumors larger than 6cm are malignant. Patient opted for surgery accepting the surgical risks. Patient underwent a successful lateral transabdominal laparoscopic left adrenalectomy with intraoperative continuous CTG monitoring. Post surgery patient had a healthy fetus on USG. She was discharged on POD-2. HPE showed a 7*8*7 cm smooth surface swelling with fleshy homogenous greyish yellow cut surface. HPE was suggestive of ganglioneuroma. She gave birth to a healthy male baby 17 weeks later. Second Case was another 26-year-old G2A1 with history of 5 months amenorrhea, Right adrenal tumor was identified incidentally on obstetric scan. No history of hypertension, paroxysmal symptoms, weight loss. USG done 2 months ago showed tumor to be 6.2*6.3 cms and interval scan after 1 month showed the lesion to be 9 *6.5 cms. On examination No cutaneous markers, BP-130/90, Striae+. ACTH and Urine 24hrs cortisol was normal. 24-hour urinary VMA was elevated (24/13). Echo and fundoscopy was normal. MR imaging showed lesion in right adrenal of 9*7.2*6 cms, hypointense on T1 and hyperintense on T2 with loss of fat planes between lesion and superior aspect of kidney. Patient underwent successful transabdominal laparoscopic right adrenalectomy with intraop- fetal monitoring. Post-op scan showed a SLIUF with AGA 23weeks 2 days. Iron, calcium and progesterone depot preparations were given post op. Mother delivered a healthy baby at term.

*Corresponding author: Dr. Vishal Naik,
Rajarajeswari Medical College and Hospital, Bangalore, India.



HPE- Globular mass of 10*8*6cms with tan yellow homogenous and soft cut surface. Microscopy showed mature ganglionic cells with large central nuclei and abundant eosinophilic cytoplasm intermixed with schwannan rich stroma. Periphery showed adrenal cortical cells. Impression- Ganglioneuroma- mature type.

DISCUSSION

Ganglioneuromas are rare tumors of peripheral nervous system (sympathetic nerve fibers) arising from neural crest cells in adrenal medulla. They are usually benign but some may progress to neuroblastoma. Commonly present in 10-40 yrs age group. Tumors are slow growing but may release certain hormones like catecholamines, VIP or androgenic hormones. Local recurrence is low, if completely excised. Surgery can be safely done in pregnancy with good outcomes, if certain precautions are adhered to. Veress needle vs open hasson entry have no difference in complication however care should be taken to modify port position according to uterine fundal height. CO2 insufflation can be safely used upto 15mm Hg to facilitate adequate visualization. Intraop capnography should be monitored. It is advisable to periodically release the pneumoperitoneum to allow physiological recovery if higher pressures are being used e.g in obese. Intraoperative sequential pneumatic compression devices and postop early ambulation are mandatory to prevent DVT. FHR monitoring should be done during surgery, or atleast pre and post-op. Tocolytics shouldn't be used prophylactically in all patients. Perioperative obstetric consultation is necessary. Risk of fetal loss is 5.8%, compared to 3.1% in open surgery. Risk off is 2.1% compared to 8.1% in open surgery.

REFERENCES

1. Magiakou M. A., Mastorakos G., Webster E., Chrousos G. P. The hypothalamic-pituitary-adrenal axis and the female reproductive system. *Annals of the New York Academy of Sciences*. 1997;816:42-56. doi: 10.1111/j.1749-6632.1997.tb52128.x. (PubMed) (CrossRef) (Google Scholar)
2. Aron D. C., Schnall A. M., Sheeler L. R. Cushing's syndrome and pregnancy. *American Journal of Obstetrics & Gynecology*. 1990;162(1):244-252. (PubMed) (Google Scholar)
3. Buescher M. A., McClamrock H. D., Adashi E. Y. Cushing syndrome in pregnancy. *Obstetrics and Gynecology*. 1992;79(1):130-137. (PubMed) (Google Scholar)
4. Lindsay J. R., Nieman L. K. The hypothalamic-pituitary-adrenal axis in pregnancy: challenges in disease detection and treatment. *Endocrine Reviews*. 2005;26(6):775-799. doi: 10.1210/er.2004-0025. (PubMed) (CrossRef) (Google Scholar)

5. Nakashima Y. M., Itonaga Y., Inoue H., Takahashi S. Pulmonary edema after laparoscopic adrenalectomy in a pregnant patient with Cushing's syndrome. *Journal of Anesthesia*. 2000;14(3):157–159. doi: 10.1007/s005400070026. (PubMed) (CrossRef) (Google Scholar)
6. Pickard J., Jochen A. L., Sadur C. N., Hofeldt F. D. Cushing's syndrome in pregnancy. *Obstetrical & Gynecological Survey*. 1990;45(2):87–93. doi: 10.1097/00006254-199002000-00002. (PubMed) (CrossRef) (Google Scholar)
7. Upadhyay A., Stanten S., Kazantsev G., Horoupian R., Stanten A. Laparoscopic management of a nonobstetric emergency in the third trimester of pregnancy. *Surgical Endoscopy and Other Interventional Techniques*. 2007;21(8):1344–1348. doi: 10.1007/s00464-006-9104-9. (PubMed) (CrossRef) (Google Scholar)
8. Sammour R. N., Saiegh L., Matter I., Gonen R., Shechner C., Cohen M., Ohel G., Dickstein G. Adrenalectomy for adrenocortical adenoma causing Cushing's syndrome in pregnancy: a case report and review of literature. *European Journal of Obstetrics Gynecology and Reproductive Biology*. 2012;165(1):1–7. doi: 10.1016/j.ejogrb.2012.05.030. (PubMed) (CrossRef) (Google Scholar)
9. Close C. F., Mann M. C., Watts J. F., Taylor K. G. ACTH-independent Cushing's syndrome in pregnancy with spontaneous resolution after delivery: control of the hypercortisolism with metyrapone. *Clinical Endocrinology*. 1993;39(3):375–379. doi: 10.1111/j.1365-2265.1993.tb02380.x. (PubMed) (CrossRef) (Google Scholar)
10. Connell J. M. C., Cordiner J., Davies D. L., Fraser R., Frier B. M., McPherson S. G. Pregnancy complicated by Cushing's syndrome: potential hazard of metyrapone therapy. Case report. *British Journal of Obstetrics and Gynaecology*. 1985;92(11):1192–1195. doi: 10.1111/j.1471-0528.1985.tb03037.x. (PubMed) (CrossRef) (Google Scholar)
11. Hána V., Dokoupilová M., Marek J., Plavka R. Recurrent ACTH-independent Cushing's syndrome in multiple pregnancies and its treatment with metyrapone. *Clinical Endocrinology*. 2001;54(2):277–281. doi: 10.1046/j.1365-2265.2001.01055.x. (PubMed) (CrossRef) (Google Scholar)
12. Wallace C., Toth E. L., Lewanczuk R. Z., Siminoski K. Pregnancy-induced Cushing's syndrome in multiple pregnancies. *The Journal of Clinical Endocrinology & Metabolism*. 1996;81(1):15–21. (PubMed) (Google Scholar)
13. Garla V., Kheetan R., Saleem T. Cushing's syndrome in pregnancy: a diagnostic conundrum. *The West Virginia Medical Journal*. 2013;109(6):34–36. (PubMed) (Google Scholar)
14. Newell-Price J., Trainer P., Besser M., Grossman A. The diagnosis and differential diagnosis of Cushing's syndrome and pseudo-Cushing's states. *Endocrine Reviews*. 1998;19(5):647–672. doi: 10.1210/er.19.5.647. (PubMed) (CrossRef) (Google Scholar)
15. Arnaldi G., Angeli A., Atkinson A. B., Bertagna X., Cavagnini F., Chrousos G. P., Fava G. A., Findling J. W., Gaillard R. C., Grossman A. B., Kola B., Lacroix A., Mancini T., Mantero F., Newell-Price J., Nieman L. K., Sonino N., Vance M. L., Giustina A., Boscaro M. Diagnosis and complications of Cushing's syndrome: a consensus statement. *Journal of Clinical Endocrinology and Metabolism*. 2003;88(12):5593–5602. doi: 10.1210/jc.2003-030871. (PubMed) (CrossRef) (Google Scholar)
16. Lindsay J. R., Jonklaas J., Oldfield E. H., Nieman L. K. Cushing's syndrome during pregnancy: personal experience and review of the literature. *The Journal of Clinical Endocrinology and Metabolism*. 2005;90(5):3077–3083. doi: 10.1210/jc.2004-2361. (PubMed) (CrossRef) (Google Scholar)
17. Newell-Price J., Bertagna X., Grossman A. B., Nieman L. K. Cushing's syndrome. *The Lancet*. 2006; 367(9522): 1605–1617. doi: 10.1016/S0140-6736(06)68699-6. (PubMed) (CrossRef) (Google Scholar)
18. Cousins L., Rigg L., Hollingsworth D., Meis P., Halberg F., Brink G., Yen S. S. C. Qualitative and quantitative assessment of the circadian rhythm of cortisol in pregnancy. *The American Journal of Obstetrics and Gynecology*. 1983;145(4):411–416. (PubMed) (Google Scholar)
