



## RESEARCH ARTICLE

### A RARE CASE REPORT OF UNCLASSIFIED MIXED GERM CELL AND SEX CORD STROMAL TUMOR OF OVARY IN ADULT FEMALE

<sup>1,\*</sup>Dr. Madhu Kumari, <sup>2</sup>Dr. Shankhanila Mazumdar, <sup>3</sup>Dr. (Prof.) Punam Prasad Bhadani, <sup>4</sup>Dr. Surabhi and <sup>5</sup>Dr. Sangam Jha

<sup>1</sup>Assistant Professor, Department of pathology, AIIMS Patna, Patna, Bihar, India

<sup>2</sup>Senior Resident, Senior Resident, Department of pathology, AIIMS Patna, Patna, Bihar, India

<sup>3</sup>Professor, Department of pathology, AIIMS Patna, Patna, Bihar, India

<sup>4</sup>Associate Professor, Department of pathology, AIIMS Patna, Patna, Bihar, India

<sup>5</sup>Additional Professor, Department of gynaecology, AIIMS Patna, Patna, Bihar, India

#### ARTICLE INFO

##### Article History:

Received 08<sup>th</sup> June, 2023

Received in revised form

20<sup>th</sup> July, 2023

Accepted 16<sup>th</sup> August, 2023

Published online 30<sup>th</sup> September, 2023

##### Key Words:

Sustainable Development Goals, Hunger, Poor man's food, Resilient crop, Sorghum.

#### ABSTRACT

Unclassified mixed germ cell and sex cord stromal tumor with yolk sac and dysgerminoma component is an infrequent ovarian neoplasm. Mixed germ cell and sex cord stromal tumors are categorized into two subtypes - gonadoblastoma and unclassified mixed germ cell and sex cord stromal cell tumor (UMGSCT). The subtype unclassified mixed germ cell and sex cord stromal tumor is rare and usually occurs in females less than 10 years of age. Here we report an uncommon case of unclassified mixed germ cell and sex cord cell stromal tumor in a 22 year old female patient. CECT lower abdomen showed a multiloculated cystic left adnexal mass. Germ cell tumour marker like alpha fetoprotein (AFP) level was elevated. Serum testosterone and DHEAS were also raised. Combining histomorphological and immunohistochemical findings a definitive diagnosis of unclassified mixed germ cell and sex cord stromal tumor was made. Conservative surgical removal is treatment of choice considering age of patient. During follow up after 6 months patient is found asymptomatic.

#### INTRODUCTION

Unclassified mixed germ cell and sex cord stromal tumor of ovary is an infrequent neoplasm comprising of derivatives of both germ cell and sex cord stromal component. Usually germ cell tumors are pure and derived from single cell lineage, whereas tumors comprising of mixed germ cell histology derived from more than one cell lineage (1). Mixed germ cell and sex cord stromal tumors are categorized into two subtypes - gonadoblastoma and unclassified mixed germ cell and sex cord stromal cell tumor (UMGSCT) (2). The subtype unclassified mixed germ cell and sex cord stromal tumor is rarer and the exact incidence is not known due to lack of data regarding this subtype. These neoplasms usually occur in females less than 10 years of age, however it can also occur in adult women. These neoplasms occur in phenotypically and genetically normal female patients, lacking the distinctive histomorphological features of gonadoblastoma (2). Surgical resection of the involved gonad is preferred management with preservation of opposite side ovary and tube. It has favourable outcome. Here we report an unusual case of unclassified mixed germ cell and sex cord cell stromal tumor in a 22 year old female patient.

#### CASE PRESENTATION

A 22 year old female presented to the gynecological out patient department with secondary amenorrhoea for 3 months and complaints of pain in abdomen and abdominal fullness for 3 months. On physical examination, there was an abdomino-pelvic mass of approximately 9 cm along with mild ascites was noted. The patient appeared to be phenotypically normal. Ultrasound whole abdomen revealed a large well defined cystic lesion with multiple septations and echoes seen within the lesion measuring approx 11.3 cm in maximum dimension in the left adnexa. CECT lower abdomen reported a multiloculated cystic left adnexal lesion measuring 9x8 cm suggesting a possibility of benign neoplastic cystic lesion. Thyroid function tests, complete blood count, kidney function test and liver function tests were within normal range. Ascitic fluid cytology was reported as suspicious for malignancy showing occasional clusters of atypical cells. Serum tumor markers level were requested and an elevation in serum AFP, testosterone and DHEAS levels were detected (Table 1). Considering age of the patient, conservative surgical management was (resection of left adnexal mass and suspicious parts of peritoneum and pouch of Douglas were resected with preserving other ovary and fallopian tube)

\*Corresponding author: Dr. Madhu Kumari,

Assistant Professor, Department of pathology, AIIMS Patna, Patna, Bihar, India.

**Table 1. Serum levels of tumor markers**

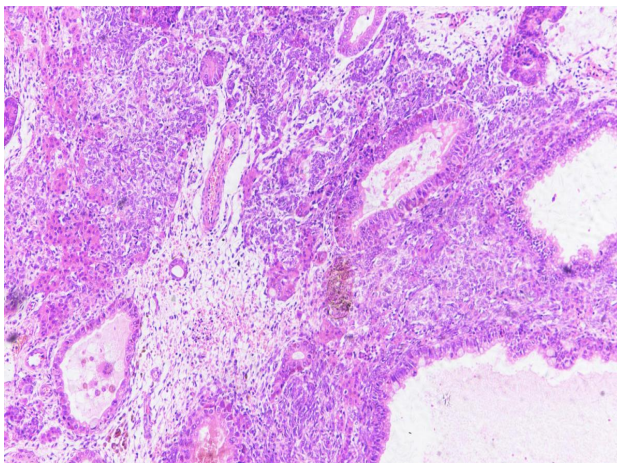
Tumor marker	Serum level
AFP	Increased
Testosterone	Increased
Dehydroepiandrosterone sukfate (DHEAS)	Increased
CA 125	Within normal range
ThCG	Within normal range
Beta HCG	Within normal range
LDH	Within normal range
Estradiol	Within normal range
FSH	Within normal range
17 OProgesterone	Within normal range
Prolactin	Within normal range

exercised. Summing up the above mentioned findings, frozen section was reported as epithelial tumor possibly benign. On gross examination, It was in multiple solid and cystic soft tissue pieces all together measured 10x8x2 cm. In histopathological examination it showed a solid and cystic tumor in which tumor cells were arranged in microcystic, reticular, macrocystic, glandular , perivascular as well as solid pattern. These cells are round to oval having mild to moderate nuclear pleomorphism, vesicular nuclear chromatin, inconspicuous to conspicuous nucleoli and moderate amount of cytoplasm.

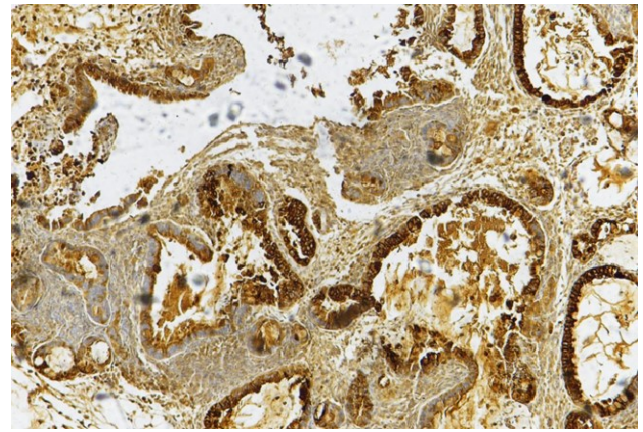
Another area showing tumor cells arranged in nests separated by fibrous septa which is infiltrated by lymphocytes. Foci of dystrophic calcification and hyaline globules seen. Focal area showing sex cord stromal differentiation also noted. On basis of above histopathological findings, it was diagnosed as mixed germ cell tumor comprising of yolk sac and dysgerminoma component. Immunohistochemistry is advised for confirmation and exact categorization. In combination with immunohistochemistry, it was finally reported as a mixed germ cell-sex cord-stromal tumour, unclassified with 80-85% yolk sac component and 15-20% dysgerminoma component (Figure 1 & 4). Multiple sections examined from ,right paracolic gutter peritoneum, left paracolic gutter peritoneum, anterior peritoneum and pouch of douglas were free of tumor. No tumor deposit noted. Immunohistochemistry were used to provide definite diagnosis (Table 2).

**Table 2. IHC markers and their interpretation**

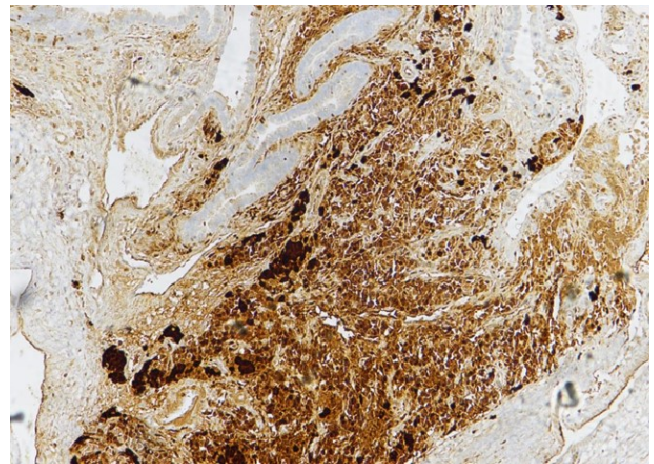
NAME OF MARKER	INTERPRETATION
CD117,PLAP & OCT4	Positive in dysgerminoma component
Alpha Feto Protein (AFP)	Positive in yolk sac component
Calretinin and inhibin	Positive in sex cord stromal component



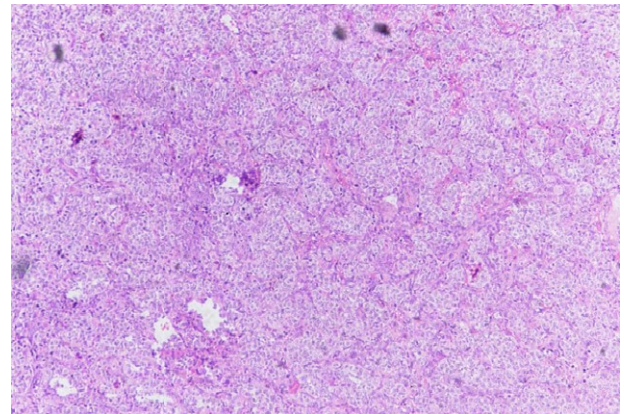
**Figure 1. Showing yolk sac component in the form of glandular pattern and sex-cord stromal cells arranged in nests and sheets (10x)**



**Figure 2. AFP IHC stains positive in yolk sac tumor and negative in sex cord stromal cells**



**Figure 3. IHC Calretinin showing positivity in sex-cord stromal component**



**Figure 4. Dysgerminoma component showing cells arranged in nests separated by fibrous septa which are infiltrated by lymphocytes**

**DISCUSSION**

Mixed germ cell and sex cord stromal tumors are classified into two types: gonadoblastoma and non gonadoblastoma type (unclassified mixed germ cell and sex cord stromal type) . Unclassified mixed germ cell and stromal tumor and gonadoblastoma are distinct from each other and are unique in their macroscopic and microscopic features . UMGSCCT commonly occurs in genetically and phenotypically normal young females, mostly in their first decade of life (3).

Origin of this tumor is not known clearly but it has been postulated that it may be due to the simultaneous transformation of germ cell and sex cord stromal derivatives. Talerman (4) first described the term unclassified mixed germ cell and sex cord stromal tumor in ovary. Till now very few cases are reported in young women (5-7). Here we are also reporting a rare case of unclassified mixed germ cell and sex cord stromal tumor in 22 yrs old female with normal phenotype. These neoplasms may present with the symptoms like abnormal uterine bleeding, abdominal pain and mass, ascites. In our case, patient presented with history of amenorrhea for 3 months along with abdominal pain and fullness. Gross features of this tumor is described as single unilateral globular mass. On cut section, it shows both solid and cystic areas. In our case, it was presented as unilateral single mass but it was received in pathology department as multiple fragmented tissue pieces exhibiting solid and cystic area. Microscopically germ cell components include dysgerminoma and yolk sac component. Dysgerminoma component will be positive for PLAP, oct3/4 and CD117. Yolk sac component will be positive for AFP and glypican 3. Sex cord stromal component may be arranged in form of trabeculae, cords, tubules and diffuse sheets and immunoreactive for calretinin and inhibin (8).

Diagnostic characteristic features of unclassified mixed sex cord stromal and germ cell tumors are described by Roth and cheng (9). According to them this tumor is comprising of malignant germ cell components in form of yolk sac tumor and dysgerminoma along with sex cord stromal components in form of cells arranged in diffuse sheets, cords and nests. Elevated serum level of tumor markers like LDH, AFP, beta HCG, testosterone are associated with these type of neoplasms depending upon the components present (10). Patients with sertoli leydig cell component in addition to serum testosterone level, serum dehydroepiandrosterone level is occasionally elevated (11). In our case, elevation in tumor markers like serum AFP, DHEAS and testosterone were observed.

Most important differential diagnosis for this type of tumor is gonadoblastoma with germ cell tumor overgrowth. UMGST must be distinguished from gonadoblastoma. UMGST occurs in female with normal genotype and phenotype as in our case, while gonadoblastoma in patients with abnormal karyotype. As gonadal genesis or chromosomal abnormalities are very rare in case of UMGST, Speleman et al. reported a case of UMGST with monosomy 22 (12). UMGST usually occurs in normal unilateral ovary as large tumor while gonadoblastoma presents with bilateral small mass (<3 cm) with gonadal dysgenesis. In our case, A phenotypically normal female presented with large unilateral ovarian mass (approximately 10 cm). Microscopically, UMGST showed variable architecture containing germ cell components with interspersed aggregates of sex cord stromal elements immunoreactive for inhibin, CD99 and calretinin, but generally lack areas of calcification and hyalinization which will be most commonly seen in gonadoblastoma.

Considering the age of the patient and unilaterality of tumor, conservative surgical removal is the treatment of choice (13). Normal contralateral ovary should be preserved as patient is in fertile age group. Whereas in case of gonadoblastoma bilateral gonads were removed as there is gonadal dysgenesis. In our case conservative surgery has been done. Patients presented with this tumor have very good prognosis after complete

surgical removal of tumor. Platinum based chemotherapy and radiotherapy are helpful in improving prognosis. Metastasis or recurrence is noted in only three reported cases (14 - 16). In our case, patient is doing well without any history of recurrence and metastasis during follow up 6 months after postsurgery.

## CONCLUSION

Here we concluded that UMGST is very rare malignancy in young female child. It is even more unusual diagnosis in adult female. It is very important to differentiate it from other differentials. Prognosis of UMGST is favourable so correct diagnosis and treatment is essential for better outcome. As this tumor occurs in fertile age group so you can preserve contralateral ovary as well. Clinical symptoms of patient, serum tumor markers, radiological and gross findings, microscopic features and immunohistochemistry will lead you to the definitive diagnosis. During follow up after six months our patient is found to be asymptomatic

## REFERENCES

1. Chen H, Quick CM, Fadare O, Zheng W: Germ cell tumors and mixed germ cell-sex cord- stromal tumors of the ovary. In *Gynecologic and Obstetric Pathology*. Zheng W, Fadare O, Quick CM, Shen D, Guo D (ed): Springer, Singapore; 2019. 2: 231-271
2. Prat J, Nogales FF, Cao D. Germ cell-sex cord stromal tumors. In: Kurman RJ, Carcangiu ML, Herrington S, Yong RH, editors. *WHO Classification of Tumours of Female Reproductive Organs*. Lyon: IARC; 2014. pp. 67-8.
3. Zuntova A, Motlik K, Horejsi J, Eckschlager T. Mixed germ cell-sex cord stromal tumor with heterologous structures. *Int J Gynecol Pathol* 1992; 11: 227-33.
4. Talerman A: A mixed germ cell-sex cord stroma tumor of the ovary in a normal female infant. *Obstet Gynecol*. 1972, 40:473-478.
5. Talerman A, Russell V. Mixed germ cell-sex cord-stromal tumor. In: Kurman RJ, editor. *Blaustin's Pathology of the Female Genital Tract*. New York: Springer; 2013. pp. 897-901
6. Arroyo JG, Harris W, Laden SA. Recurrent mixed germ cell-sex cord-stromal tumor of the ovary in an adult. *Int J Gynecol Pathol* 1998; 17: 281-3.10.1097/00004347-199807000-00015.
7. Jacobsen GK, Braendstrup O, Talerman A. Bilateral mixed germ cell sex-cord stroma tumour in a young adult woman. Case report. *APMIS Suppl* 1991; 23: 132-7. <https://pubmed.ncbi.nlm.nih.gov/1652994/>
8. Metwalley KA, Elasers DA, Farghaly HS, Abdel-Lateif H, Abdel-Kader M: Precocious puberty secondary to a mixed germ cell-sex cord-stromal tumor associated with an ovarian yolk sac tumor: a case report. *J Med Case Rep*. 2012, 6:162. 10.1186/1752-1947-6-162
9. Roth LM, Cheng L: Gonadoblastoma: origin and outcome. *Hum Pathol*. 2020, 100:47-53. 10.1016/j.humpath.2019.11.005
10. Min K, Choi B, Kim KR: Mixed germ cell-sex cord-stromal tumor of non-gonadoblastoma type of ovary: a case report. *Korean J Pathol*. 2002, 36:62-65. [www.jpatholm.org/upload/pdf/kjp-36-1-62.pdf](http://www.jpatholm.org/upload/pdf/kjp-36-1-62.pdf)
11. Gutierrez S, Bermudez M, Zylberstein C, Naredo E, Illanes L, Scaglia HE: LH receptor in testosterone-producing

- ovarian tumor. In vivo and in vitro HCG-stimulated testosterone production. *Eur J Gynaecol Oncol* 1983,4:182–191. [pubmed.ncbi.nlm.nih.gov/6313366/](https://pubmed.ncbi.nlm.nih.gov/6313366/)
12. Speleman F, Dermaut B, De Potter CR, Van Gele M, Van Roy N, De Paepe A, Laureys G: Monosomy 22 in a mixed germ cell-sex cord-stromal tumor of the ovary . *Genes Chromosomes Cancer*. 1997, 19:192-194. [10.1002/\(SICI\)1098-2264\(199707\)19:3<192::AID-GCC9>3.0.CO;2-T](https://doi.org/10.1002/(SICI)1098-2264(199707)19:3<192::AID-GCC9>3.0.CO;2-T)
  13. Saenz J, Rodriguez J, Beltran M, et al. (July 23, 2020) Unclassified Mixed Germ Cell-Sex Cord-Stromal Tumor of the Ovary: An Unusual Case Report. *Cureus* 12(7): e9350. DOI [10.7759/cureus.9350](https://doi.org/10.7759/cureus.9350)
  14. Talerman A, Roth LM: Recent advances in the pathology and classification of gonadal neoplasms composed of germ cells and sex cord derivatives. *Int J Gynecol Pathol*. 2007, 26:313-321. [10.1097/01.pgp.0000250148.52215.ce](https://doi.org/10.1097/01.pgp.0000250148.52215.ce)
  15. Pang S, Zhang L, Shi Y, Liu Y: Unclassified mixed germ cell-sex cord-stromal tumor with multiple malignant cellular elements in a young woman: a case report and review of the literature. *Int J Clin Exp Pathol*. 2014, 7:5259-5266. <https://www.ncbi.nlm.nih.gov/pmc/articles/PMC4152097/>
  16. Lacson AG, Gillis D, Shawwa A: Malignant mixed germ-cell-sex cord-stromal tumors of the ovary associated with isosexual precocious puberty. *Cancer*. 1988, 61:2122-2133. [10.1002/1097-0142\(19880515\)61:10<2122::AID-CNCR2820611032>3.0.CO;2-7](https://doi.org/10.1002/1097-0142(19880515)61:10<2122::AID-CNCR2820611032>3.0.CO;2-7)

\*\*\*\*\*