www.ijramr.com

ISSN : 2350-0743

International Journal of Recent Advances in Multidisciplinary Research
Vol. 06, Issue 02, pp.4677-4680, February, 2019

RESEARCH ARTICLE

POSTOBSTRUCTIVE NEGATIVE PRESSURE PULMONARY EDEMA

*[1]Lourdes Trinidad Castillo García, [2]Denise Yuliana Vázquez Bautista and [3]Natxielhy Fabiola Canseco Cuevas

[1]Anesthesiologist/Pain Medicine, Department of Anesthesiology, American British Cowdray Medical Center, Mexico
[2,3]Anesthesiologist, Department of Anesthesiology, American British Cowdray Medical Center, Mexico

ARTICLE INFO

Article History:
Received 12th November, 2018
Received in revised form
24th December, 2018
Accepted 20th January, 2019
Published online 28th February, 2019

Keywords:
Acute pulmonary negative pressure edema (NPPE),
Upper airway obstruction,
Hypoxia,
Hyperadrenergic state

Corresponding author:
Dr. Lourdes Trinidad Castillo García

ABSTRACT

Acute pulmonary negative pressure edema (NPPE) also known as post-obstructive pulmonary edema is a life-threatening clinical scenario in which pulmonary edema develops immediately after upper airway obstruction. A review of the literature suggests that in healthy adults undergoing general anesthesia the incidence of NPPE is estimated at 0.05% to 0.1% .4,5. The pathophysiology of post obstructive pulmonary edema is multifactorial, with components of pulmonary edema of negative pressure, hypoxia and hyperadrenergic state. Hypoxia and a hyperadrenergic state are other factors that contribute to the development of EPPN. Hypoxia can increase pulmonary vascular resistance and pulmonary capillary pressure. It can also alter capillary integrity and precipitate a hyperadrenergic state. It is believed that a hyperadrenergic response redistributes blood from the systemic veins to the pulmonary circuit and increases pulmonary vascular resistance. All these events can promote the formation of edema. Finally, hypoxia and acidosis can depress myocardial performance and aggravate pulmonary edema.2In the clinical presentation, initial findings usually include decreased oxygen saturation, with foamy pink foam and abnormalities on the chest x-ray.20 Manifestations of acute airway obstruction include stridor, supraslary and supraclavicular retractions, urgent use of accessory muscles of inspiration and panic in facial expression. As NPPE develops, auscultation usually reveals crackles and occasional wheezing. Pulmonary edema causes both impaired oxygen diffusion and lack of ventilation / perfusion matching, leading to sudden and possibly severe hypoxemia. The typical chest radiograph will show diffuse interstitial and alveolar infiltrates. Treatment strategies vary according to the severity of the symptoms of POPE but are similar for type I treatment and type II. Support measures include the maintenance of a patent. Airway and ensuring adequate oxygenation through supplements. Oxygen with the addition of positive end expiratory pressure (PEEP) or continuous positive airway pressure guided by physical examination, pulse oximetry and arterial blood gases determinations.

INTRODUCTION

Acute pulmonary negative pressure edema (NPPE) also known as post-obstructive pulmonary edema is a life-threatening clinical scenario in which pulmonary edema develops immediately after upper airway obstruction. Two distinct subclasses of the EPPN have been described in the literature: type I is associated with intense inspiratory effort in the setting of acute airway obstruction, while type II occurs after relief of chronic obstruction of the airways. respiratory tract. The common etiologies for type I EPPN include laryngospasm, epiglottitis, CRUP, presence of foreign body, strangulation, hanging, obstruction of the endotracheal tube, laryngeal tumor, goiter, mononucleosis or postoperative vocal cord paralysis. Type II is more common after relief of a chronic partial obstruction of the upper respiratory tract, as can be expected after an adenoidectomy or tonsillectomy, as well as after a correction of choanal stenosis1. In the adult population, EPPN ismorecommonlycausedbylaryngospasmandtumorsoftheupper airways, while in the pediatric population, epiglottitis, CRUP and laryngotracheobronchitis are the most common etiologies (Van Kooy and Gargiulo, 2000). The most common cause of acute post-obstructive pulmonary edema is laryngospasm. It is known that EPPN occurs as a consequence of laryngospasm in more than 50% of patients (Suzuki *et al.,* 2014).

Epidemiology

A review of the literature suggests that in healthy adults undergoing general anesthesia the incidence of NPPE is estimated at 0.05% to 0.1% .4,5 However, in adult and pediatric patients requiring urgent tracheal intubation or tracheotomy to relieve upper airway obstruction, the incidence is reported to be 11% to 12% .6,7. Se ha sabe que los adultos jóvenes sanos (especialmente los atletas masculinos) tienen un mayor riesgo de desarrollar EPPN en el postoperatorio inmediato. Este hallazgo resulta de que lógicamente los pacientes jóvenes sanos son fisiológicamente capaces de generar una presión intratorácica negativa suficientemente grande para inducir algunos de los cambios fisiopatológicos asociados con el edema pulmonar. Los factores de riesgo adicionales para el desarrollo del EPPN en el contexto perioperatorio incluyen difilcultad en la intubación, patología quirúrgica localizada en faringe, nariz o boca, la obesidad con apnea obstructiva del sueño, cuello corto y acromegalia.[8,9] Otros autores también han asociado el EPPN con el uso de opioides, parálisis de cuerdas vocales, oclusión del tubo endotraqueal, extubación prematura, estrechamiento de la tráquea intratorácica (tráquea en vaina de sable) y en caso de hipo durante la inducción en niños (Dicpinigaitis and Mehta, 1995; Soldano *et al.,* 1993; Jacka and Persaud, 1999; Stuth *et al.,* 2000).

Physiology

The pathophysiology of postobstructive pulmonary edema is multifactorial, with components of pulmonary edema of negative pressure, hypoxia and hyperadrenergic state. The main component is negative pressure pulmonary edema that develops in patients with type I PNPE. The pathophysiology of EPPN is derived from the markedly negative chest pressure induced by inspiratory effort against an obstructed glottis, which is also known as the Müller maneuver. Healthy adults can generate a negative inspiratory pressure of up to -140 cm H2O (Cook and Mead, 1960). This event leads to an increase in venous return and blood flow to the right side of the heart, as well as a decrease in flow from the left side as a result of the increase in afterload (Lang *et al.,* 1990). This combination causes increased pulmonary blood volume and increased pulmonary venous pressures, which lead to increased hydrostatic pressures and edema formation (Fig. 1) 17. In addition, as a result of elevated negative intrapleural pressure due to obstruction, pressure is transmitted to the interstitium and alveoli and causes an increase in the hydrostatic gradient that favors the transudation of fluid from the pulmonary capillary to the interstitial space of the lung, resulting in pulmonary edema (Lang *et al.,* 1990; Guffin *et al.,* 1995). The increase in negative pressure is the possible component that explains why healthy young men who generate higher negative intrapleural pressures have a higher incidence of NPPE (Deepika *et al.,* 1997). The etiological factors that lead to type II EPPN are less clear than what has been described for type I. The pathophysiology of type II PAPE focuses more on expiration against an obstructed airway. Expiration against an upper airway obstruction is similar to performing a Valsalva maneuver and causes positive alveolar and pleural pressures, resulting in decreased venous return, decreased pulmonary blood volume, and decreased preload right and left ventricular (Lang *et al.,* 1990; Guffin *et al.,* 1995). In this way, once the obstruction has been eliminated, as in the case of adenotonsillectomy, the sudden relief causes an abrupt fall in airway pressure, an increase in venous return and a consequent increase in preload. However, because the left ventricular function has already been compromised, it is unable to match the production needed for the sudden increase in venous return and preload. This results in an elevation of the hydrostatic pressure in the pulmonary circuit that leads to pulmonary edema by the elimination of an obstruction. (Figure 1) (Guffin *et al.,* 1995; Ringold *et al.,* 2004).

Hypoxia and a hyperadrenergic state are other factors that contribute to the development of EPPN. Hypoxia can increase pulmonary vascular resistance and pulmonary capillary pressure. It can also alter capillary integrity and precipitate a hyperadrenergic state. It is believed that a hyperadrenergic response redistributes blood from the systemic veins to the pulmonary circuit and increases pulmonary vascular resistance. All these events can promote the formation of edema. Finally, hypoxia and acidosis can depress myocardial performance and aggravate pulmonary edema (Lang *et al.,* 1990). It is important to know that the primary determinants of the rate of formation of pulmonary edema, or fluid passage, from the capillary interstitium to the alveolar interstitium are transvascular gradients of osmotic and hydrostatic pressure and of the vascular permeability of proteins, according to the model of the Starling equation for the passage of transcapillary fluid:

$$Qf = K [(Pmv-Pi) - \sigma (\pi mv-\pi i)]$$

where Qf is the net flow of fluid from the capillary lumen to the alveolar interstitium; K is the coefficient of capillary permeability; Pmv is the hydrostatic pressure of the capillary lumen; Pi is the alveolar interstitial hydrostatic pressure; σ is the reflection coefficient (the effectiveness of the vascular barrier in preventing the diffusion of the protein); πmv is the osmotic microvascular pressure of the protein; and πi is the osmotic pressure of the interstitial protein. fifteen

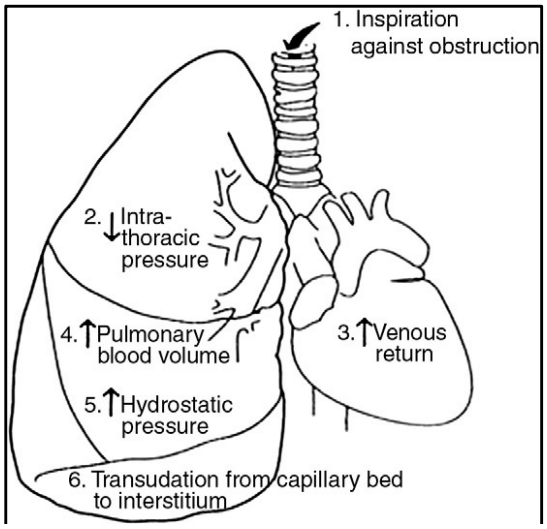

Figure 1. Physiopathology

The normal hydrostatic difference between the intravascular and extravascular compartments of the lung favors filtration of the steady-state fluid from the capillaries to the interstitium; This filtering is eliminated by the pulmonary lymphatic vessels. If a positive equilibrium develops from increases in the hydrostatic or protein osmotic gradient, the pulmonary lymphatic flow increases. When the rate of interstitial fluid accumulation exceeds the capacity of lymphatic drainage, the edema fluid accumulates in the interstitium and fills the alveolus, becoming clinically detectable either by arterial oxygen desaturation, new opacities on chest radiographs, appearance of fluid of edema in the endotracheal tube or expectoration by the non-intubated patient (Bhattacharya *et al.,* 2016).

Clinical presentation

In the clinical presentation, initial findings usually include decreased oxygen saturation, with foamy pink foam and abnormalities on the chest x-ray (Lathan *et al.,* 1999). Manifestations of acute airway obstruction include stridor, supraslary and supraclavicular retractions, urgent use of accessory muscles of inspiration and panic in facial expression. As NPPE develops, auscultation usually reveals crackles and occasional wheezing. Pulmonary edema causes both impaired oxygen diffusion and lack of ventilation / perfusion matching, leading to sudden and possibly severe hypoxemia. The typical chest radiograph will show diffuse interstitial and alveolar infiltrates (Figure 2). Although the radiographic findings associated with pulmonary edema following extubation have been described, there is minimal data on the distribution of this post-tubular edema within the lungs (Cascade *et al.,* 1993). NPPE has a characteristic appearance in computed tomography (CT). Unlike other forms of pulmonary edema, the computed tomography sections showed a surprising central preferential

distribution and not dependent on the attenuation of the polished crystal (edema / hemorrhage), which is parallel to the pleural and interstitial pressure gradients. Both pressures tend to be more negative in the central and non-dependent regions than in the peripheral and dependent lung regions, respectively, and these regional pressure differences tend to increase with inflation and inspiratory effort. As a result, interstitial and, therefore, perivascular pressures tend to decrease more in the central and non-dependent regions, and changes in transmural vascular pressure and capillary stress should be maximum in those regions.

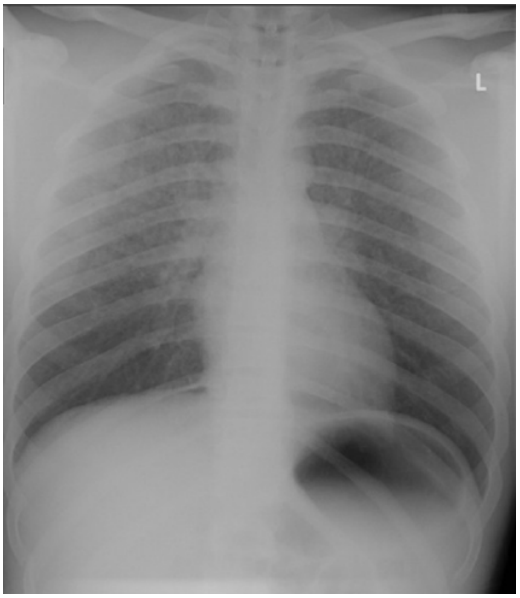

Figure 2. Chest x-ray of a patient with low-pressure postoperative pulmonary edema showing interstitial and alveolar infiltrates.

Differential diagnosis

The diagnosis of NPPE is usually made on the basis of a history of a precipitating incident and symptoms. NPPE requires rapid intervention and can be confused with other causes of postoperative respiratory distress. The presence of agitation, tachypnea, tachycardia, pink foamy lung secretions, rales and progressive oxygen desaturation suggest the diagnosis of NPPE in the appropriate place. Chest radiography findings of pulmonary edema support the diagnosis. Other causes of pulmonary edema should be considered [Table 2]. The measurement of the fluid pulmonary edema / plasma protein ratio is a well-validated method to differentiate between hydrostatic pulmonary edema and pulmonary edema with higher permeability (Cascade *et al.,* 1993). Airway and ensuring adequate oxygenation through supplements. Oxygen with the addition of positive end expiratory pressure (PEEP) or continuous positive airway pressure guided by physical examination, pulse oximetry and arterial blood gases determinations. In general, the addition of PEEP or continuous positive airway pressure will lead to rapid resolution of pulmonary edema. In severe cases, the patient may require mechanical ventilation with PEEP and 100% FIO2 (Davidson *et al.,* 2004). The recommended initial level of PEEP to improve oxygenation, lung compatibility and ventilation / perfusion mismatch (V / Q) it is 5 to 10 cm H2O (Ortiz-Gómez *et al.,* 2006). Diuretics have also been administered, especially for those patients who received aggressive intraoperative fluids Some authors have recommended the use of diuretics in an attempt to decrease the intravascular volume and alter the Starling equation in favor of intracapillary filtration and resolution of edema (Reséndiz *et al.,* 2009). But nevertheless, diuretics can exacerbate hypovolaemia and hypoperfusion in surgical patients, and therefore, their role in POPE remains uncertain (Jacka and Persaud, 1999). Although it is believed that steroids decrease the physical damage suffered by the alveoli and capillaries of POPE's high negative pressures, its role is also controversial (Alcázar Villar Ma *et al.,* 1998). Recognition of clinical scenarios in which airway, an obstruction is likely to occur, you must identify early and can start precautions. A management of anesthesia. The plan to avoid obstruction should include adequate anesthesia depth during mask ventilation, a patient fully awake before extubation, and consideration of intubation with fiber optics in patients with known airway abnormalities (Kesimci *et al.,* 2007).

Table 2. Differential diagnosis of post-obstructive post obstructive pulmonary edema according to the mechanism of onset

Imbalance of starling forces	Altered alveolar–capillary membrane permeability (acute respiratory distress syndrome)
Increased pulmonary capillary pressure	Infectious pneumonia—bacterial, viral, parasitic
Increased pulmonary venous pressure without left ventricular failure (eg, mitral stenosis)	Inhaled toxins (eg, phosgene, ozone, chlorine, teflon fumes, nitrogen dioxide, smoke)
Increased pulmonary venous pressure secondary to left ventricular failure	Circulating foreign substances (eg, snake venom, bacterial endotoxins)
Increased pulmonary capillary pressure secondary to increased pulmonary arterial pressure (so-called over perfusion pulmonary edema)	Aspiration of acidic gastric contents
Decreased plasma oncotic pressure	Acute radiation pneumonitis
Hypoalbuminemia	Endogenous vasoactive substances (eg, histamine, kinins)
Increased negativity of interstitial pressure	Disseminated intravascular coagulation
Rapid removal of pneumothorax with large applied negative pressures (unilateral)	Immunologic—hypersensitivity pneumonitis, medications (nitrofurantoin), leukoagglutinins
Large negative pleural pressures as a result of acute airway obstruction alone with increased end-expiratory volumes (asthma)	Shock lung in association with nonthoracic trauma
	Acute hemorrhagic pancreatitis
Lymphatic insufficiency	Unknown or incompletely understood
After lung transplant	High-altitude pulmonary edema
Lymphangitic carcinomatosis	Neurogenic pulmonary edema
Fibrosing lymphangitis (eg, silicosis	Narcotic overdose
	Pulmonary embolism
	Eclampsia
	After cardioversion
	After anesthesia

Treatment

Treatment strategies vary according to the severity of the symptoms of POPE but are similar for type I treatment and type II. Support measures include the maintenance of a patent.

DISCUSSION

It is estimated that there is an incidence of laryngospasm of 9 in 1000 procedures under general anesthesia (Deepika *et al.,* 1997). Of these, about 10% of patients may develop pulmonary edema (Deepika *et al.,* 1997; Ringold *et al.,* 2004). The physiological development of acute post-obstructive lung edema is attributed to the neurogenic (hyperadrenergic) and cardiac or hydrostatic mechanisms.20 During normal breathing negative pressures are generated from -5 to -2 cm of water, and expiratory pressures near the 10 cm of water; However, inspiratory efforts can generate negative pressures of up to -100 to -140 cm of water. In asthmatic patients or with some type of high airway obstruction, negative pleural pressures have been documented between -50 and -70 cm of water (Lathan *et al.,* 1999; Cascade *et al.,* 1993). The clinical effects of these negative intrapleural pressures produce the rupture of the alveolocapillary membrane which leads to the leakage of liquid to the areas of gaseous exchange of the lung. This exudative process is characterized by a liquid rich in protein compared to blood plasma (Lathan *et al.,* 1999; Cascade *et al.,* 1993; Bhattarai and Shrestha, 2011). The exaggerated negative intrapleural pressure redistributes the blood from the venous

system to the pulmonary circulation, which results in an increase in the pulmonary blood volume, which could be associated with the hydrostatic mechanism. Cardiac function can be directly affected by significant negative intrapleural pressures, through the increase in left ventricular filling pressures, a mechanism not related to increased lung volume but with an increase in sympathetic tone and the release of catecholamines., with the subsequent increase in preload, afterload and decrease in the ejection fraction of the left ventricle. Finally, hypoxemia that occurs in acute post-obstructive pulmonary edema produces pulmonary arterial vasoconstriction that is associated with redistribution of the pulmonary circulation, decreased interstitial hydrostatic perivascular pressure and transmural pulmonary vascular pressure (arterial, capillary and venous) with increased pulmonary intravascular pressures, all of which promote leakage of fluid into the pulmonary interstitium (Van Kooy and Gargiulo, 2000; Lathan *et al.,* 1999; Cascade *et al.,* 1993; Bhattarai and Shrestha, 2011). Dysneic symptoms usually develop immediately after extubation, although late cases have been reported up to a few hours after the surgical procedure; soon the classic serosanguineous sputum appears, related to the rupture of the alveolocapillary membrane and the passage of erythrocytes to the alveolar spaces (Van Kooy and Gargiulo, 2000; Devys *et al.,* 2000). This clinical condition affects predominantly young people and children. Strong young patients with short neck, history of apnea and Mallampatti classification greater than or equal to 3 are recognized as risk factors. The higher incidence in athletes is related to the ability of these patients to generate greater intrapleural negative pressures for longer periods of time. prolonged As criteria for poor prognosis, the underlying cardiovascular disease and the poor pulmonary reserve are described (Devys *et al.,* 2000 Vandse *et al.,* 2012). These patients usually show significant improvement and resolution of symptoms in the first 36 hours, with supplemental oxygen only; however, about 20% require continuous positive pressure in the airway, and of these, about 65% improve with non-invasive mechanical ventilation, and 45% require invasive mechanical ventilation (Van Kooy and Gargiulo, 2000; Suzuki *et al.,* 2014; Lathan *et al.,* 1999).

REFERENCES

Alcázar Villar Ma. J, López-Herce Cid J, Sancho-Pérez L, Cebrián Pazos J, Carrillo Álvarez A. 1998. Edema agudo de pulmón por laringoespasmo tras la recuperación de una anestesia general. *An Esp Pediatr.,* 48:660-62.

Bhattacharya, M. Kallet, R. 2016. Negative-Pressure Pulmonary Edema. *CHEST*, 150(4):927-933

Bhattarai B, Shrestha S. 2011. Negative pressure pulmonary edema case series and review of literature. *Kathmandu Univ Med J (KUMJ),* 9(36):310-315.

Cascade PN, Alexander GD, Mackie DS. 1993. Negative-pressure pulmonary edema after endotracheal intubation. *Radiology*., 186:671–5. [PubMed]

Cook CD, Mead J. 1960. Maximum and minimum airway pressures at various lung volumes in normal children and adults. *Fed Proc.,* 19(1):377

Davidson S, Guinn Ch, Gacharna D. 2004. Diagnosis and treatment of negative pressure pulmonary edema in a pediatric patient: a case report. *AANA Journal,* 72(5):337-38.

Deepika K, Kenaan CA, Barrocas AM, *et al.* 1997. Negative pressure pulmonary edema after acute upper airway obstruction. *J Clin Anesth.,* 9:403-8.

Devys JM, Balleau C, Jayr C, Bourgain JL. 2000. Biting the laryngeal mask: an unusual cause of negative pressure pulmonary edema. *Can J Anaesth.,* 47(2):176-178.

Dicpinigaitis PV. and Mehta DC. 1995. Postobstructive pulmonary edema induced by endotracheal tube occlusion. *Intensive Care Med.,* 21:1048-50.

Guffin TN, Har-el G, Sanders A, *et al.* 1995. Acute postobstructive pulmonary edema. *Otolaryngol Head Neck Surg.,* 112(2):235-7.

Holmes JR, Hensinger RN. and Wojtys EW. 1991. Postoperative pulmonary edema in young, athletic adults. *Am J Sports Med.,* 19:365-71.

Jacka MJ, Persaud S. 1999. Negative-pressure pulmonary edema associated with Saber-sheath trachea. *Anesthesiology*, 90(4):1209-11.

Kanter RK, Watchko JF. 1984. Pulmonary edema associated with upper airway obstruction. *Am J Dis Child,*128:356-8.

Kesimci E, Aslan B, Gümüs T, Kanbak O. 2007. Management of unpredıcted postoperatıve Negatıve Pressure Pulmonary edema: A Report of Two Cases. *The Internet Journal of Anesthesiology,* 12(1):7.

Lang SA, Duncan PG, Shephard DA, *et al.* 1990. Pulmonary oedema associated with airway obstruction. *Can J Anaesth.,* 37(2):210-8.

Lathan SR, Silverman ME, Thomas BL, Waters WC. 1999. Postoperative pulmonary edema. *South Med J.,* 92:313–5.

Lorch DG, Sahn SA. 1986. Post-extubation pulmonary edema following anesthesia induced by upper airway obstruction. Are certain patients at increased risk? *Chest*, 90(6):802-05.

Lorch DG. and Sahn SA. 1986. Post-extubation pulmonary edema following anesthesia induced by upper airway obstruction. Are certain patients at increased risk?, *Chest*, 90:802-5.

McConkey PP. 2000. Postobstructive pulmonary edema a case series and review. *Anaesth Intensive Care,* 28(1):72-6.

N D´Souza, Garg R. 2008. Perioperative laryngospasm- review of literature. *The Internet Journal of Anesthesiology.*

Olsson GL, Hallen B. 1984. Laryngospasm during anesthesia. A computeraided incidence study in 136,929 patients. *Acta Anaesthesiol Scand.,* 28:567-75.

Ortiz-Gómez JR, Plaja-Marti I, Sos-Ortigosa F, Pérez-Cajaraville JJ, Arteche-Andrés MA, *et al.* 2006. Edema pulmonar por presión negativa: a propósito de 3 casos. *An Sist Sanit Navar.,* 29(2):269-74.

Oswalt CE, Gates GA, Holmstrom MG. 1977. Pulmonary edema as a complication of acute airway obstruction. *JAMA*, 238:1833–35.

Reséndiz MT, Matadamas LS, Revilla E. 2009. Edema pulmonar de presión negativa y hemorragia pulmonar, reporte de una caso y revisión de la literatura. *Revista de la Asociación Merxicana de medicina Crítica y Terapia Intensiva,* 23(1):47-51.

Ringold S, Klein EJ, Del Beccaro MA. 2004. Postobstructive pulmonary edema. *Pediatr Emerg Care,* 20(6):391-5.

Saquib M, Ahmad M, Khan RA. 2011. Development of negative pressure pulmonary oedema secondary to postextubation laryngospasm. *Anaesth Pain & Intensive Care,* 15(1):42-4

Soldano SL, Place LB, Edwards FH, *et al.* 1993. Post-extubation non-cardiogenic pulmonary edema. *Mil Med.,* 158:278-80.

Staub NC. 1974. Pulmonary edema. *Physiol Rev.,* 54(3):678-811.

Stuth EAE, Stucke AG, Berens RJ. 2000. Negative-pressure pulmonary edema in a child with hiccups during Induction. *Anesthesiology*, 93:282-4.

Suzuki M, Inagi T, Kikutani T, Mishima T, Bito H. 2014. Negative pressure pulmonary edema a er reversing rocuronium-induced neuromuscular blockade by sugammadex. *Case Rep Anesthesiol.,* 135032.

Tami TA, Cu F, Weldes TO, *et al.* Pulmonary edema and acute upper airway obstruction. Laryngoscope 1986;86:506-9.

Van Kooy MA, Gargiulo RF. 2000. Postobstructive pulmonary edema. *Am Fam Physician.,* 62(2):401-4.

Vandse R, Kothari DS, Tripathi RS, Lopez L, Stawicki SP, Papadimos TJ. 2012. Negative pressure pulmonary edema with laryngeal mask airway use: Recognition, pathophysiology and treatment modalities. *Int J Crit Illn Inj Sci.,* 2(2):98-103.

Wu RG. 2015. Negative pressure pulmonary edema. *J Intern Med Taiwan,* 26:63-8.

****