



ISSN : 2350-0743

www.ijramr.com



International Journal of Recent Advances in Multidisciplinary Research

Vol. 05, Issue 04, pp.3713-3715, April, 2018

## RESEARCH ARTICLE

### TELESCOPIC REMOVAL OF BULLET IN A CHALLENGING CASE OF GUNSHOT INJURY

**\*Dr. Nilam U. Sathe, Dr. Sheetal Shelke, Dr. Ratnapriya and Dr. Shampa Mishra**

Department of ENT and Head, Neck Surgery, Seth G. S. Medical College and KEM Hospital, Parel, Mumbai - 400 012, India

#### ARTICLE INFO

##### Article History:

Received 18<sup>th</sup> January, 2018

Received in revised form

25<sup>th</sup> February, 2018

Accepted 09<sup>th</sup> March, 2018

Published online 30<sup>th</sup> April, 2018

##### Keywords:

Gunshot injury:

Telescopic removal.

#### ABSTRACT

**Introduction:-** The incidence of gunshot wounds to the face have been on a rise but still are rare compared to firearm injuries to other regions of the body. Such injuries can be devastating due to the presence of vital structures in the vicinity. We describe a rare case of retained bullet in the infratemporal fossa which presented with delayed onset facial palsy and was meticulously removed with the help of 0 degree endoscope.

**Case Report:** - A male patient aged 36 years reported to the emergency department of KEM hospital for management of gunshot injury to left side of face. The trauma was as a result of homicidal gunshot injury. However, 6 days following the episode the patient developed left sided facial palsy. Computerised tomography of the face revealed presence of metallic foreign body impacted in the infratemporal fossa with associated fracture of the mandibular condyle and temporal bone fracture. The bullet was located in a critical position only within 5mm of carotid artery. Upper part of the condylar process along with the condylar head was removed for better access. Hopkins 0 degree endoscope was used to further trace the entry wound down up to the infratemporal fossa.

**Conclusion:** - The successful outcome depends on careful planning and multidisciplinary team approach. In our case, we would also like to highlight that the use of endoscope was extremely helpful and helped us to avoid the morbidity associated with external approach.

#### INTRODUCTION

Firearm wounds in the maxillofacial facial region comprise fourteen percent of all gunshot related assaults. Though the incidence of gunshot wounds to the face have been on a rise but still are rare compared to firearm injuries to other regions of the body (Sansare *et al.*, 2011). Such injuries can be devastating due to the presence of vital structures in the vicinity. Controversaries surround regarding the ideal time and treatment in these cases (Kennedy *et al.*, 200). Here we describe a rare case of retained bullet in the infratemporal fossa which presented with delayed onset facial palsy and was meticulously removed with the help of 0 degree endoscope.

#### Clinical Case

A male patient aged 36 years reported to the emergency department of KEM hospital for management of gunshot injury to left side of face. The trauma was as a result of homicidal gunshot injury following which patient had a brief episode of loss of consciousness and was shifted to nearby private hospital. Later on for further management patient was referred to KEM and got admitted in general surgery ward. Surprisingly, the patient was stable and did not present with profuse bleeding, head injury or any other significant

complaint. At that time, he only complained of pain in left side of the face and difficulty in opening mouth and was treated conservatively with wound cleaning and intravenous antibiotics. However, 6 days following the episode the patient developed left sided facial palsy and was the subsequently transferred to the ENT ward for management of the same. On examination, there was 1 X 1 cm entry wound in left pre auricular region, tenderness over the left temporomandibular joint and left sided grade IV LMN facial palsy. The external auditory canal on the left was filled with blood clot. Computerised tomography of the face revealed presence of metallic foreign body impacted in the infratemporal fossa with associated fracture of the mandibular condyle and temporal bone fracture. The bullet was located in a critical position only within 5mm of carotid artery. Though the initial plan of management was conservative but due to development of delayed onset facial palsy patient was taken up for removal of the bullet under general anaesthesia. Due to proximity of the bullet to carotid artery and associated condylar fracture and facial palsy, the patient was taken up for removal of bullet under general anaesthesia in the ENT OT along with maxillofacial facial surgeon, plastic surgeon and the cardiovascular thoracic team stand by during the case. Linear preauricular incision was taken behind the entry wound, just anterior to the tragus. Entry wound was clearly visualised. Branches of the facial nerve were identified and preserved. Then, the root of zygoma and zygomatic arch was exposed and the left temporomandibular joint capsule was opened with

**\*Corresponding author: Dr. Nilam U. Sathe,**

Department of ENT and Head, Neck Surgery, Seth G. S. Medical College and KEM Hospital, Parel, Mumbai - 400 012, India.

complete exposure of the condylar head which was found to be fractured and the fracture segments were carefully and completely removed. Upper part of the condylar process along with the condylar head was removed for better access. Hopkins 0 degree endoscope was used to further trace the entry wound down up to the infratemporal fossa. The bullet was found embedded in the infratemporal fossa just next to visible pulsations of the carotid artery. The bullet was disimpacted from the surrounding tissues very gently using the ear ball point and delivered very carefully using the endoscope. Condylar plating and the left eye tarsorrhaphy was also done in the same sitting. Post operative period was uneventful. Post operative computerised tomography showed complete removal of the bullet.

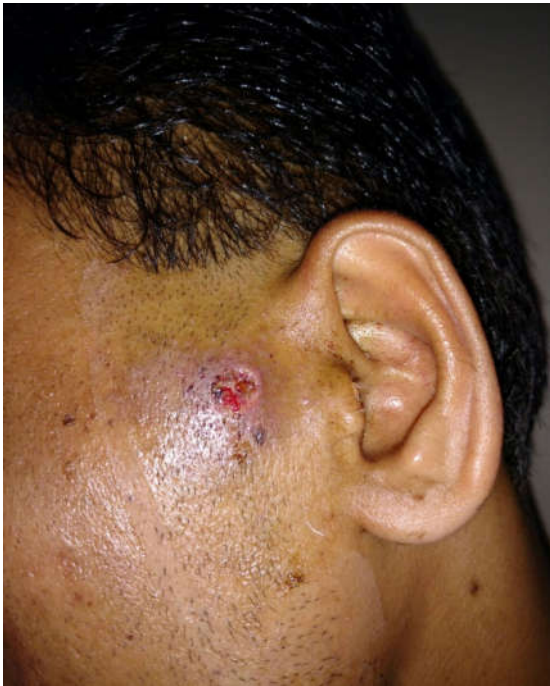

Figure 1. Showing entry wound of Bullet in left preauricular area

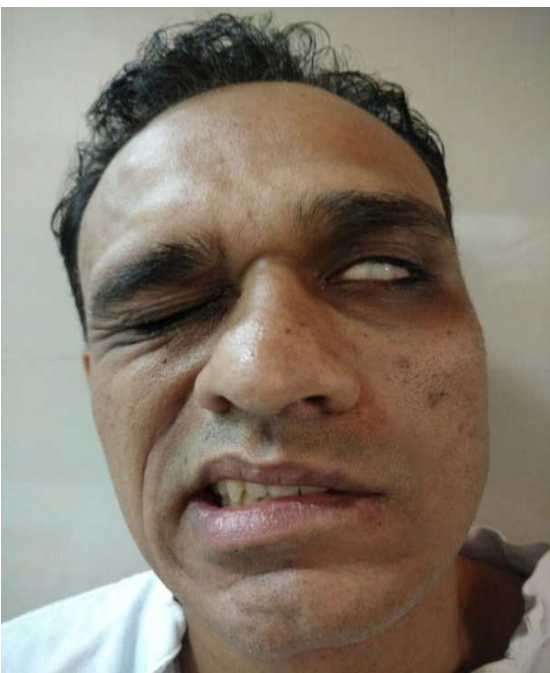

Figure 2. Patient showing left sides lower motor neuron facial nerve palsy

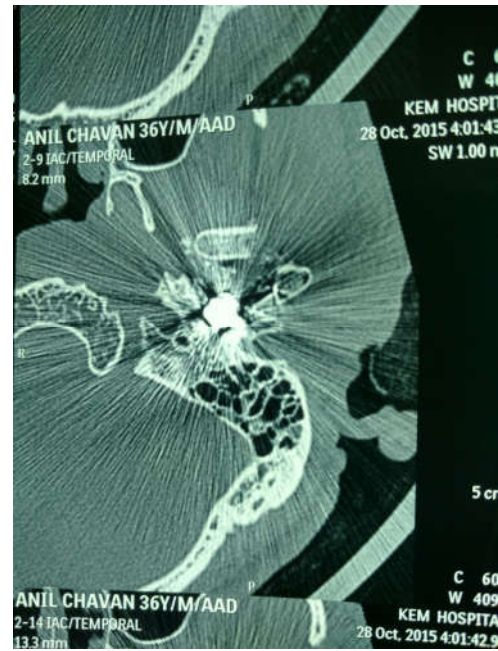


Figure 3. CT Scan showing Bullet in Infratemporal fossa

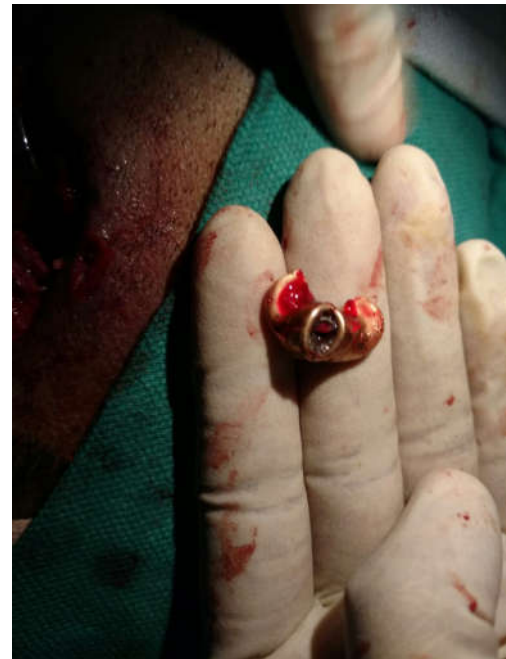

Figure 4. Showing the Bullet Removed From Infratemporal Fossa

### DISCUSSION

Foreign bodies in the head and neck region are often difficult to remove and the approach depends on its size and relationship to nearby vital structures (Edwaldo Dourado *et al.*, 2008). Gunshot injuries are often associated with significant morbidity and mortality. Such injuries in the maxillofacial region have unusual and complicated presentation (Saidi *et al.*, 2002). The problems encountered are not only due to the gunshot injury but even its surgical removal may cause life threatening complications owing to its proximity to crucial anatomical structures (robe *et al.*, 2011). The factors affecting the extent of gunshot injuries include type of the weapon, distance from which patient has been shot, velocity of bullet (low velocity, less than 1000 feet/sec and high velocity, more than 2000 feet/sec) and tissue resistance. The fundamental classification consists of three classes i.e. penetrating, perforating, and avulsive.

Low-velocity projectiles often cause penetrating wounds which have small entrance and exit wounds. On the contrary, high-velocity projectiles mostly cause perforating wounds which pass right through tissues and have small entry wounds and somewhat larger exit wounds (Dimitroulis, 2006). Further, gunshot injuries can be classified into three types depending on the range from which bullet has been shot, where type 1 consists of those penetrating only subcutaneous tissue and fascia (long range, over 7 yards), type 2 includes those penetrating internal cavities (3–7 yards) and blast injuries come under type 3 (less than 3 yards).

Type 2 and 3 injuries may lead to severe tissue damage and fracture of bones. Also, subject to the tract that is formed by the bullet trajectory, the injuries can be divided into four groups: (1) through and through wound (2) tangential damage in the absence of any entry or exit wound (3) bullet retained in body and palpable under skin. (4) Bullet retained in body and not palpable under skin (Hauer *et al.*, 2011; Bartlett *et al.*, 2000; Kennedy *et al.*, 2000). According to this classification our patient belonged to type 4 (bullet residing in the infratemporal fossa). By and large gunshot injuries are treated conservatively as the surgical procedures may pose a greater risk than that associated with systemic lead intoxication as a result of retained bullet (Kikano *et al.*, 1992). In our case, since the patient did not have any significant complaints at the outset, hence was managed conservatively initially with intravenous antibiotics and wound cleaning and dressing and was kept under observation. In bone and soft tissue, the retained bullets are surrounded by fibrous scar with very little vascularisation, hence preventing dissolution of lead (Greenberg, 1990). However, some cases of arthropathy (Jansen *et al.*, 1995) and systemic lead intoxication in patients have been described where bullets were in contact with synovial and cerebral spinal fluids (Cavalieri Costa *et al.*, 1994).

Owing to physical and chemical properties, metallic lead dissolves in acidic media leading to toxic effects such as the central and peripheral neuropathy, nephropathy and haemolytic anaemia (Cavalieri Costa *et al.*, 1994). As retained bullet may lead to poisoning, fistula formation, recurrent infections, or secondary haemorrhage, its removal has been seemed necessary even in the absence of clinical symptoms (Lee *et al.*, 1997). When retained bullet causes plumbism, some non-specific symptoms have usually been found to be associated with this condition which consist of; anorexia, vomiting, constipation, abdominal pain and rarely anaemia and renal toxicity, but even acute encephalopathy with lethargy, stupor and coma could be there, in extreme cases (Mahajan and Shah, 2004). Here, in our case though the patient did not show any signs of systemic lead intoxication but developed late onset LMN grade 4 facial palsy 6 days following the assault and this made the removal of the bullet a necessity. Thus we went ahead and took the patient for removal under general anaesthesia with the help of maxillofacial surgeon and plastic surgeon and successfully removed the bullet from the infratemporal fossa using 0 degree endoscope. It has been seen that the outcome significantly improves with proper diligent planning and skilled team (Vanna Long *et al.*, 2002).

## Conclusion

Hence we would like to conclude that foreign body in the maxillofacial region is a diagnostic challenge for the otorhinolaryngologist. The successful outcome depends on careful planning and multidisciplinary team approach. In our case, we would also like to highlight that the use of endoscope was extremely helpful and helped us to avoid the morbidity associated with external approach.

## REFERENCES

- Bartlett, CS., Helfet, DL., Hausman, MR., Strauss, E. 2000. Ballistic and gunshot wounds: Effects on musculoskeletal tissues. *J Am Acad Orthop Surg.*, 8:21–36. [PubMed]
- Cavalieri Costa, R., Stape, CA., Suzuki, I., Targa, WH., Batista MA., Bernabe, AC., Miranda, FG. and Lage, LA. 1994. Lead poisoning caused by bullet in the hip. Report of 2 cases. *Rev Hosp Clin Fac Med São Paulo*, 49:124-7.
- Dimitroulis, G. 2006. An unusual bullet trajectory to the face. *J Oral Maxillofac Surg.*, 64:137–139. [PubMed]
- Edwaldo Dourado, Ana Claudi Amorim Gomes, et al. 2008. Surgical removal of metallic foreign in face-Case report. *Odontologia Clin Cientif Recife*, 37(2):161-164.
- Greenberg, SR. 1990. The histopathology of tissue leads retention. *Histol Histopathol.*, 5:541-6.
- Hauer, T., Huschitt, N., Kulla, M., Kneubuehl, B. and Willy, C. 2011. Bullet and shrapnel injuries in the face and neck regions. *Current aspects of wound ballistics*, HNO. 59:752–64. [PubMed]
- Jansen, DL., Tirman, PF., Rabassa, AE. And Kumar, S. 1995. Lead bursogram and focal synovitis secondary to a retained intrarticular bullet fragment. *Skeletal Radiol.*, 24:142-4.
- Kennedy, F., Sullivan, J., Arellano, D. and Roulier, R. 2000. Evaluating the role of physical and radiological examination in assessing bullet tract termination for gunshot victims. *Am Surg.*, 66:296–301.
- Kikano, GE. and Stange, KC. 1992. Lead poisoning in a child after a gunshot injury. *J Farm Pract*, 34:498-500.
- Lee, D., Nash, M., Turk, J., Har-El, G. 1997. Low-velocity gunshot wounds to the paranasal sinuses. *Otolaryngol Head Neck Surg.*, 116:372–378.
- Mahajan, M. and Shah, N. 2004. Accidental lodgment of an air gun pellet in the maxillary sinus of a 6-year old girl: a case report. *Dent Traumatol.*, 20:178–180.
- Saidi, HS., Nyakiamo, J. and Faya, S. 2002. Gunshot injuries as seen at the Aga Khan Hospital, Nairobi, Kenya. *East Afr Med J.*, 79:188–192.
- Sansare, K., Khanna, V. et al. 2011. The role of maxillofacial radiologist in gunshot injuries-a hypothesized missile trajectory in two case reports. *Dentomaxillofacial Radiology*, 40:53-59.
- Vanna Long., Lun-Jou Lo, et al. 2002. Facial Reconstruction after a complicated gunshot injury. *Chang Gung Med J.*, 25:557-562.

\*\*\*\*\*